

# Gastrointestinal Stromal Tumor

---

# *Understanding Your GIST Pathology Report*



**Jason L. Hornick, MD PhD**  
*Harvard Medical School  
Brigham and Women's Hospital*

**Alexander J.F. Lazar, MD PhD**  
*Sarcoma Research Center  
University of Texas M. D. Anderson Cancer Center*

**Edited by Julia Doswell Royster, PhD**  
*Science Coordinator, GIST Support International*



## How You Can Use this Booklet



After your surgery, you can discuss your gastrointestinal stromal tumor (GIST) with your surgeon and your oncologist using this booklet as background. Ask for copies of your surgeon's report about the operation, plus your pathology report. Then request your physicians to explain the characteristics of your tumor and its prognosis, as well as your treatment options.

### Questions to Ask Your Doctors:

1. Where was my tumor located?
2. How large was my tumor?
3. Were any portions of my digestive organs removed along with the tumor?
4. Was there only a single primary tumor, or was there any metastasis (spread)?
5. Were the surgical margins "clean" (R0 or negative margins, free from tumor cells)?
6. What was the mitotic rate (an indication of tumor cell growth rate)?
7. What is the risk of recurrence or metastasis for my tumor? Please show me where my tumor falls in the risk groups shown in this booklet.
8. Should I consider drug therapy after I recover from surgery?
9. Did my tumor have any characteristics that indicate I should get genotyping done now to identify the tumor's mutation status?
10. What is the appropriate plan for my follow-up monitoring and treatment?
11. Do I need to alter my diet to ensure good nutrition considering the surgical changes to my gastrointestinal tract?



## Why is my pathology report important to me?

Your pathology report provides the diagnosis of the tumor that you had biopsied or surgically removed: gastrointestinal stromal tumor (GIST). The specific tumor characteristics described in your pathology report help to determine which treatments are most appropriate for you. Your oncologist will use the pathology report to help plan your treatment. You should discuss your report with your oncologist to understand your GIST and your treatment choices.



## What is a pathologist?

A pathologist is a medical doctor who diagnoses diseases by examining tissues, cells and bodily fluids. In the case of GIST, the pathologist examines tissue from biopsies and surgeries. Although the surgeon may suspect GIST on the basis of pre-surgery imaging and the appearance of the tumor during surgery, only the pathologist can determine that the tumor is truly a GIST. After examining and testing the tissue from your tumor in the laboratory, the pathologist describes tumor characteristics that can predict how likely it is for your GIST to come back (recur) or to spread (metastasize) to your liver, your abdominal cavity, or rarely to other body parts.

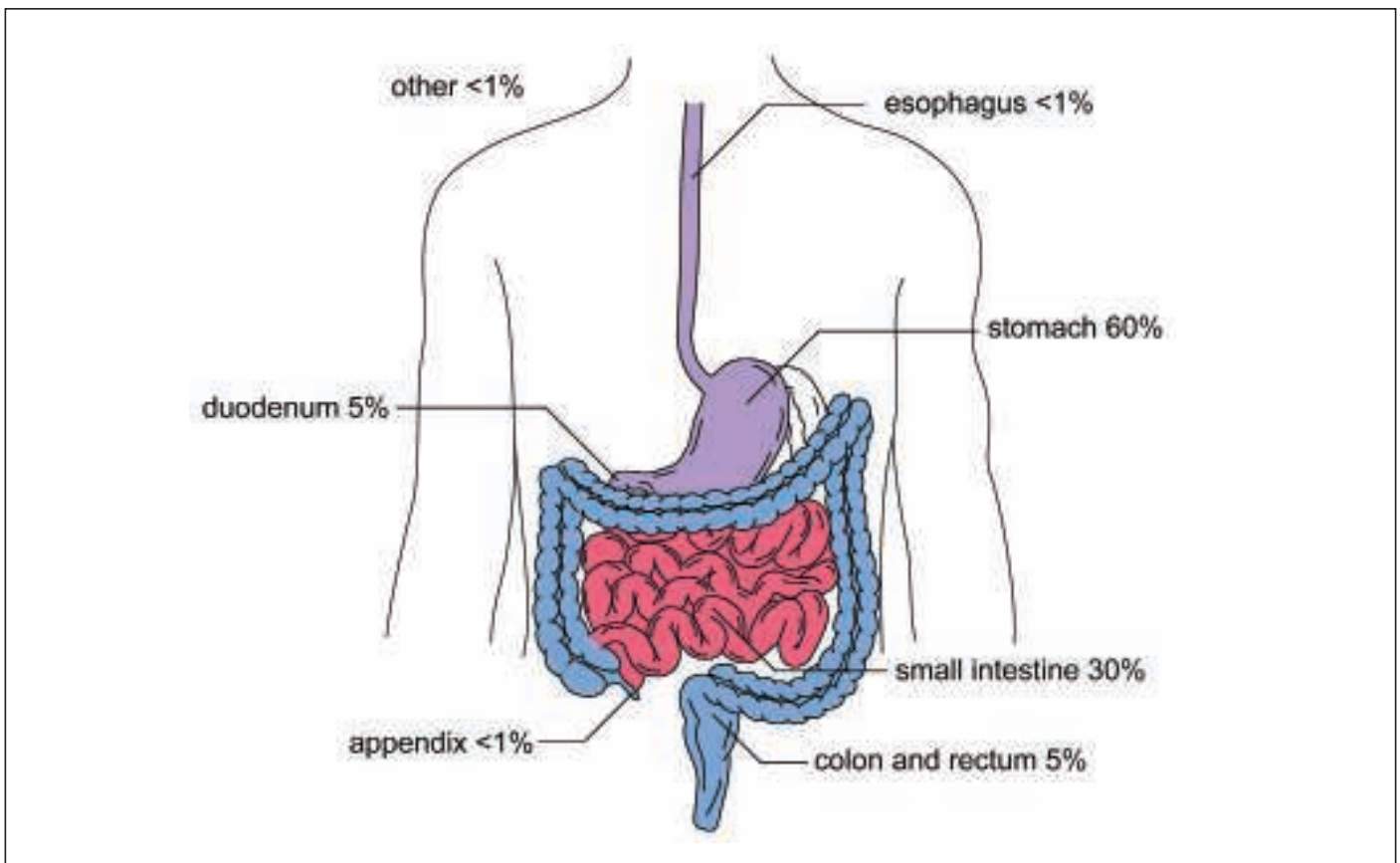
Although patients seldom meet pathologists, these physicians are crucial to your treatment because they:

- Analyze pre-surgery biopsies to render a diagnosis
- Diagnose GIST versus alternative tumor types to determine the therapeutic approach
- Assess the adequacy of surgical margins after an operation
- Determine the risk category (probability of recurrence) for primary tumors
- Confirm any metastases already present at diagnosis
- Provide the data to help decide whether the drug therapy imatinib will be used after a complete surgical resection of the primary tumor.

## What is a GIST?

Gastrointestinal stromal tumor (GIST) is a rare cancer usually affecting the digestive tract or occasionally nearby structures within the abdomen. GIST is a type of sarcoma. Sarcomas are tumors that develop in tissues that connect, support, or surround other structures and organs of the body. Sarcoma cells resemble malignant versions of the normal cells within connective or supportive tissues such as bone, cartilage, tendons, nerves, fat, muscle, or blood vessels. (In contrast to sarcomas, most abdominal cancers are carcinomas that arise from the lining of organs, and their cells more closely resemble epithelial or glandular tissue.) GISTs most commonly develop in the wall of the stomach or small intestine. GIST cells have some features similar to the normal interstitial cells of Cajal, which are involved in maintaining normal gut function (peristalsis).

Less than 1% of GISTs initially occur outside of the organs shown in Figure 1.



**Figure 1. Distribution of GIST in the organs of the gastrointestinal tract.**

Occasionally, a GIST will develop from membranes within the abdomen (such as the omentum and mesentery) rather than being directly attached to the digestive tract itself. GIST most frequently metastasizes (spreads) to the liver or the abdominal membranes (peritoneum, omentum, and mesentery).

## Diagnosing GIST

Usually GIST is diagnosed from the visual features of the tumor cells, plus tests to confirm the presence of the protein KIT (also called CD117) in the tumor cells. KIT protein is detected by immunohistochemistry (a special laboratory technique to detect proteins in cells). In addition, the absence of other proteins that are seldom expressed by GIST can also be useful diagnostically. Although a few other abdominal tumors can rarely test positive for KIT, the pathologist can use the results from a panel of tests to differentiate among the possible diagnoses. Those few GISTs that are negative for KIT protein can be identified by an expert pathologist using additional tests.

### What is KIT protein (CD117)?

KIT protein (or CD117) is a cell-surface receptor for a growth factor called stem cell factor. Normally, KIT triggers cell division, cellular differentiation, or other cellular functions *only* when KIT is stimulated by stem cell factor.

In the gastrointestinal tract, the KIT receptor is present on cells called interstitial cells of Cajal, or ICCs. These special cells control peristalsis, the GI tract move-

**Unlike common GI cancers, GISTs begin within the wall of the digestive organs (not the lining) and usually grow outward.**

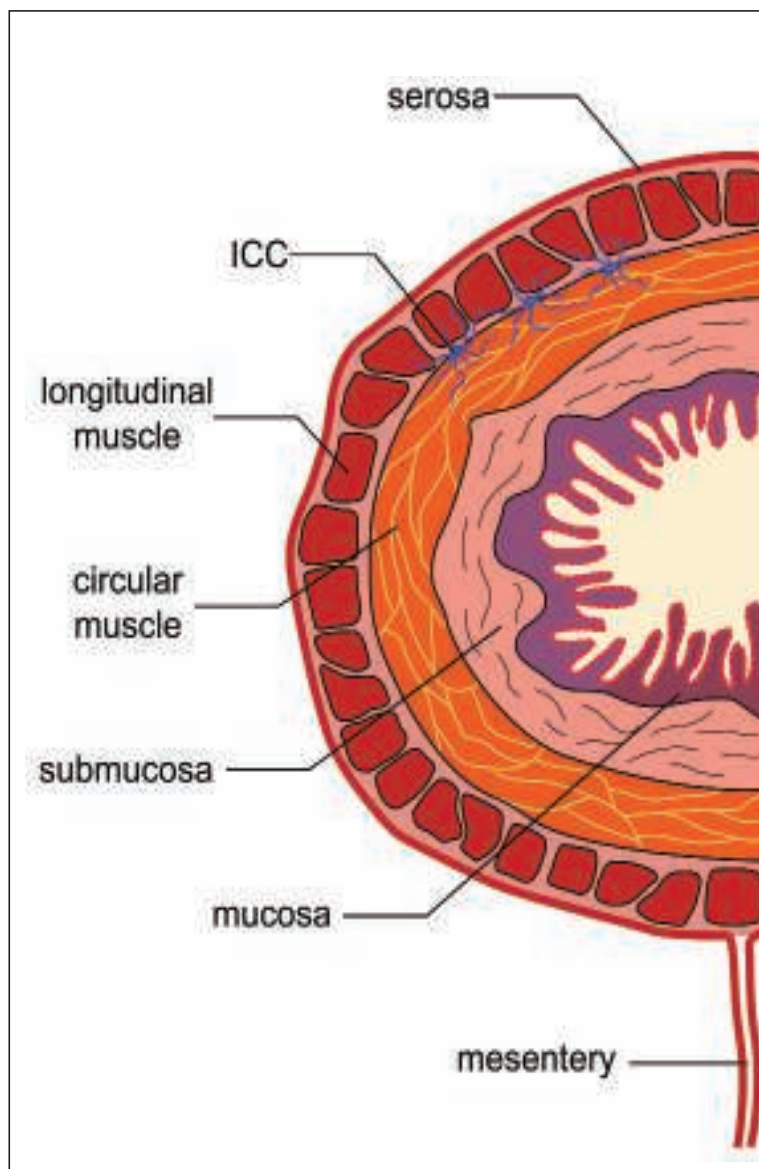
ments that propel food along as it is digested. Because GIST cells show the same type of differentiation as ICCs (or may even be derived from stem cells that produce ICCs), the tumor cells test positive for KIT in almost all GISTs.

The ICCs are located between the layers of the muscular wall of the GI tract, as shown in Figure 2. This could represent the wall of any digestive organ except the esophagus, which lacks the outermost serosal covering. Common cancers (carcinomas) start from within the lining (mucosa) of the GI tract and often initially grow inside the digestive organs.

At first the GIST is contained within the wall (called intramural), but as it grows larger it usually extends outward into the abdominal cavity. Occasionally a GIST may grow into the hollow tube of the digestive tract (called its lumen). Frequently GISTs ulcerate the lining at their point of origin and cause bleeding into the GI tract. This blood loss and the resulting anemia may be the symptoms that bring the GIST to the attention of the patient and the physician.

## Do KIT mutations cause GIST?

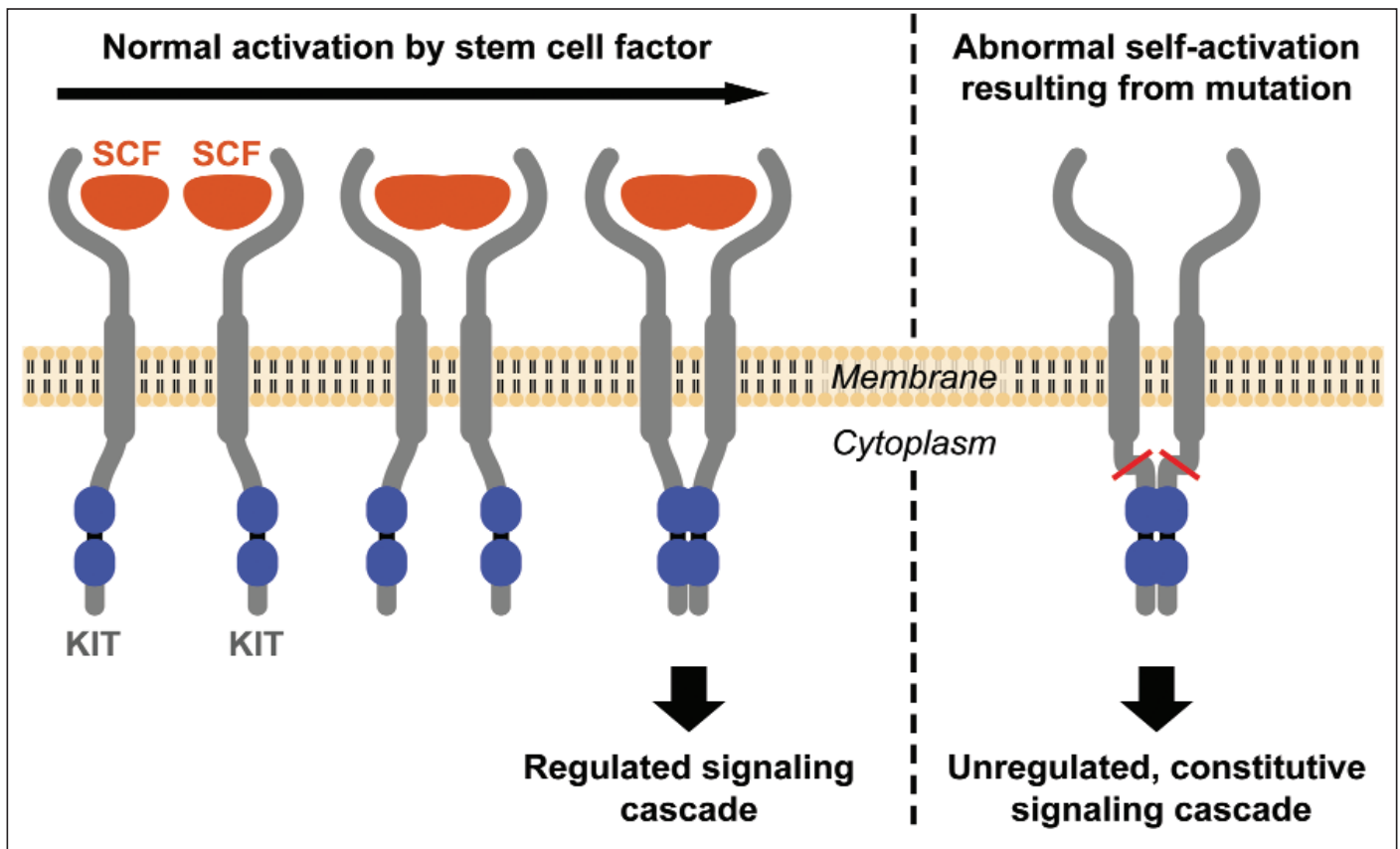
Yes, in about 80% of GISTs, KIT protein that is abnormally activated due to a mutation in the KIT gene causes uncontrolled cell division



**Figure 2. Cross-section showing the layers of the gastrointestinal tract. The ICCs are the star-shaped cells in blue (not to scale) between the longitudinal and circular muscular layers.**

and tumor growth. KIT is a transmembrane protein: it straddles the cell membrane with a part extending outside of the cell (the extracellular domain) and a part extending into the interior of the cell (the intracellular or cytoplasmic domain).

The growth factor called stem cell factor (SCF, also known as KIT ligand) binds two receptors at once and causes activation of the KIT receptor pair. When the growth factor locks into place between the exterior parts of two KITs to form a receptor pair, they change orientation and the portions inside the cell membrane come closer together. This allows each member of the pair to activate the other at an “activation loop” location inside the cell membrane, as shown in the left panel of Figure 3. (The activation process is called “phosphorylation” because chemically this involves transfer of a phosphate group).



**Figure 3. Two KIT receptors normally form a pair when stimulated by the ligand stem cell factor (SCF) to initiate downstream signaling (left sequence). Mutations cause the KIT receptors to display abnormal constitutive signaling without stimulation from the SCF ligand (right).**

The activated KIT starts a series of signals to the cell nucleus, triggering the cell to enter the cell cycle and reproduce by cell division (called mitosis). In normal ICCs, KIT triggers cell division only when a cell needs to be replaced due to age or injury. In contrast, in most GISTs, a mutation in the KIT gene causes the KIT receptors to signal abnormally for continuous cell growth as shown in the right panel of Figure 3.

This uncontrolled growth causes a GIST to form. About 80% of GISTs are caused by a mutated KIT gene and the resulting malformed KIT protein that triggers abnormal cell division and tumor growth.

Other abnormalities of GIST cells that occur later in the tumor's development also play a role in how aggressive the tumor becomes, but abnormal KIT activation is the primary cause in the majority of GISTs. Therapeutic drugs such as imatinib and sunitinib turn off the abnormal signaling by binding to the intracellular portion of the KIT receptor to prevent activation.

### **Are all GISTs caused by mutations in the KIT gene?**

No, there are two types of GIST with normal KIT genes.

**PDGFRA-mutant GIST:** About 5%-10% of GISTs have normal KIT genes but are caused by an activating mutation in the gene for a different growth factor receptor called platelet-derived growth factor receptor alpha (PDGFRA). Normally, these PDGFRA receptor pairs join and signal the cell nucleus in just the same way as shown above for KIT, except that the growth factor that stimulates them is platelet-derived growth factor (PDGF). If the PDGFRA gene is mutated, then the protein PDGFRA can signal for continuous cell growth without being stimulated by PDGF, causing a GIST to grow.

**Wild-type GIST:** Tumors that do not have activating mutations in either the KIT or PDGFRA genes are called wild-type GISTs. Their growth triggers have not yet been identified. These wild-type GISTs comprise about 10%-15% of GISTs, including the majority of GISTs diagnosed in patients under 30 years old. As more research is done, this group will probably be divided into more



subgroups with genetic abnormalities that have not yet been identified. A small number of these cases are already known to have mutations in the oncogene BRAF.

## **Do all GISTs test positive for KIT protein?**

About 95% of GISTs are positive for the presence of KIT protein using immunohistochemistry (a special laboratory technique to detect proteins in cells). Almost all GISTs caused by a mutated KIT gene and almost all wild-type GISTs test positive for KIT. Some GISTs caused by a mutated PDGFRA gene test negative or very weakly for KIT protein when the pathologist stains

**95% of GISTs test positive for KIT protein, but other methods can identify KIT-negative GISTs.**

the cells. It is not currently easy to test for PDGFRA staining directly because the commercially available reagents are not yet reliable enough for general use. A few specialized pathology labs may perform PDGFRA immunohistochemical testing. Alternatively, mutation testing of the PDGFRA gene may be recommended for diagnosis of KIT-negative GIST. While it is becoming increasingly used in GIST cases, mutation testing is not always part of a pathology report and some physicians are comfortable managing GIST patients without this information.

If the pathologist suspects that a tumor is a GIST but the KIT test results are weak or negative, then alternative tests can help identify the tumor type. For example, newer protein markers such as DOG1 (which stands for discovered on GIST 1) can be helpful for diagnosing GISTs that lack KIT protein expression.

## Is KIT testing always reliable?

The validity of immunohistochemical testing for KIT expression depends on the pathologist's methodology and experience to avoid false positive results. Commercially available test materials are much more reliable now than they were in 2000-2002, when false positives occurred more frequently. If there is doubt, a tumor sample can be sent for a second opinion to a pathologist with more sarcoma expertise.

**Mutation testing (genotyping) of tumor tissue is not part of a typical GIST pathology report.**

## Is mutation testing needed for GIST diagnosis and prognosis?


No, mutation testing (also called genotyping) is not necessary for diagnosis of KIT-positive GIST, and it is not part of a typical GIST pathology report. Although some GIST treatment centers do routinely perform mutation testing on GISTs, this is not currently standard practice. Your pathologist may decide that mutation analysis is needed in the case of KIT-negative GIST, or if unusual tumor cell characteristics make diagnosis difficult. Your pathologist or your oncologist may decide that mutation analysis would be helpful in managing your treatment if there is reason to suspect an unusual genotype that would affect your response to drug therapies. Also see questions 8-10 later in this booklet, and more details at [www.gistsupport.org](http://www.gistsupport.org)

Genotyping is done only in a limited number of labs; therefore, samples must be shipped for mutation testing unless you are being treated at one of the specialty centers with this capability. Regardless of whether genotyping is done locally or by an external lab, it will be reported separately, either as a subsequent addendum to your pathology report or as an entirely separate report.

# Pathology Samples

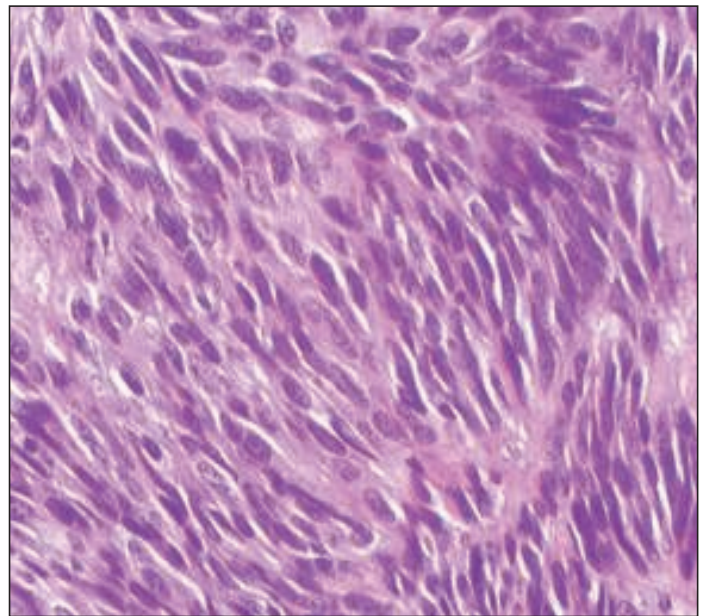
**S**ometimes GIST diagnosis is made using biopsy samples obtained before any surgery is attempted. A biopsy is performed only when knowing the diagnosis will change the next step in treatment. For example, if a small tumor might be a type that would not require removal, then the biopsy results could allow unnecessary surgery to be avoided. For large tumors, if pre-surgery treatment with imatinib might shrink the tumor and reduce the scope of surgery, or if shrinkage might make it possible to resect a tumor that currently appears inoperable, then biopsy is definitely needed to diagnose GIST before imatinib can be prescribed.

In contrast, if a pre-surgery biopsy would not change the surgeon's plans to remove (resect) the tumor, then the diagnosis may be postponed until after the operation. For example, this might happen when a tumor is large enough to require removal regardless of what type it is, and pre-treatment with imatinib is not needed to improve resectability. All the tissue removed during an operation is called the surgical specimen. The entire specimen is sent to the surgical pathologist, who selects areas of the specimen to examine under the microscope.



## How Are Pathology Specimens Prepared for Analysis?

When a biopsy sample or a surgical specimen arrives at the pathology department, the pathologist follows this general sequence of steps. In the case of a biopsy, the entire specimen is used for analysis. In the case of a surgical resection specimen, sampling occurs so that representative portions of the tumor can be analyzed. The portions of tissue are cut thin, then fixed in formalin, which makes the tissue more firm. The specimens are treated with heat, pressure, and solvents to remove lipids and to suffuse wax (called paraffin) into the tissue. Then the specimens are embedded in larger blocks of wax that will allow very thin slices to be cut and placed on glass slides. These slides are then de-paraffinized so that the tissue can be stained with water-based dyes and other reagents.



The initial stains are with hematoxylin and eosin that stain the cell nuclei (containing the DNA) blue and stain the cytoplasm and most other structures pink, as shown in this sample. H&E stains allow visualization of the shapes of the cells and the architecture of the tissue, which helps the pathologist to make a diagnosis. These stains also allow the pathologist to determine the mitotic rate, which suggests how fast the tumor is growing.

In the case of suspected GIST, the pathologist then performs immunohistochemical tests to look for expression of KIT and other protein markers to help confirm the diagnosis.

If additional tests are needed, further slides can be cut for this purpose. After final diagnosis, the glass slides and paraffin blocks are carefully stored for future patient needs or for research.

## How quickly will my pathology results be available?

Processing the samples can take up to a week. The pathologist then sends a report to your physician, usually a surgeon and/or medical oncologist. They may need to discuss the case at an internal conference to produce a full interpretation. Sometimes materials may need to be sent out for additional testing or review by an expert pathologist, and this will extend the time to a final diagnosis. If mutation testing of the KIT or PDGFRA gene is needed, this can often take two weeks or more after the initial diagnosis.

# Pathology Analyses for GIST

**A**lthough the level of detail depends upon whether the sample is a tiny biopsy or an entire surgically resected tumor, the pathologist generally follows the same basic protocol:

- To describe the type of sample and its visual appearance to the naked eye (called macroscopic description or gross description)
- To describe characteristics of the tissue when viewed under a microscope (called microscopic description)
- To perform immunohistochemical tests that detect the presence or absence of certain proteins that can identify the type of cells composing the tumor.

## Gross Description

In the macroscopic or gross description section of the report, the pathologist will record the visible features such as:

- **Extent of specimen**, including any organs removed with the tumor
- **Origin of the tumor** (the point along the GI tract where the tumor arose)
- **Size of the tumor** measured in centimeters (2.54 cm = 1 inch)

- **Invasion or adherence** to other organs (if present)
- **Areas of necrosis** (dead tissue) or cystic degeneration.

## **Surgical Margins**

Surgeons attempt to remove a margin of normal tissue around the point of origin of the GIST to minimize the chances of cells being left behind that could grow later, causing local recurrence. In addition, the surgeon may remove sections of structures adjacent to the GIST if the tumor was adherent to them; in this case a margin of normal tissue will also be sought on the resected part of the adjacent structure. The distances to the margins are measured in the gross specimen and then all margins are examined microscopically with emphasis on the margin(s) closest to the tumor. Usually the gross and microscopic assessments are similar, but sometimes the microscopic examination reveals something not seen with the naked eye, and in this case, the microscopic margin is the assessment that is present in the final report. Margins are described as follows:

**R0 resection** indicates complete removal of all tumor with microscopically negative margins showing no evidence of tumor cells (“clean” margins).

**R1 resection** indicates that the margins of the resected parts show tumor cells when viewed microscopically (microscopically positive margins).

**R2 resection** indicates that portions of tumor visible to the naked eye were not removed (macroscopically positive margins).

## **Microscopic Description: Morphology and Histology**

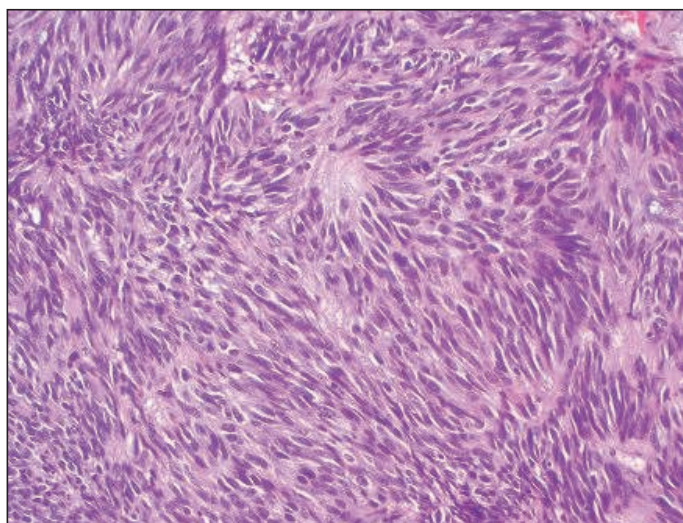
Morphology refers to the characteristics of individual cells, and histology refers to the description of the microscopic structure of tissues. You could think of tissue structure as similar to the grain of wood. The pathologist will comment on the overall organization of the tumor cells as viewed on prepared slides, as well as features of individual cells. For these observations, the pathologist usually uses H&E slides (slides stained with hematoxylin and eosin). Hematoxylin

stains cell nuclei blue, and eosin stains other cell parts pink. Using H&E is standard to help the pathologist view cells better.

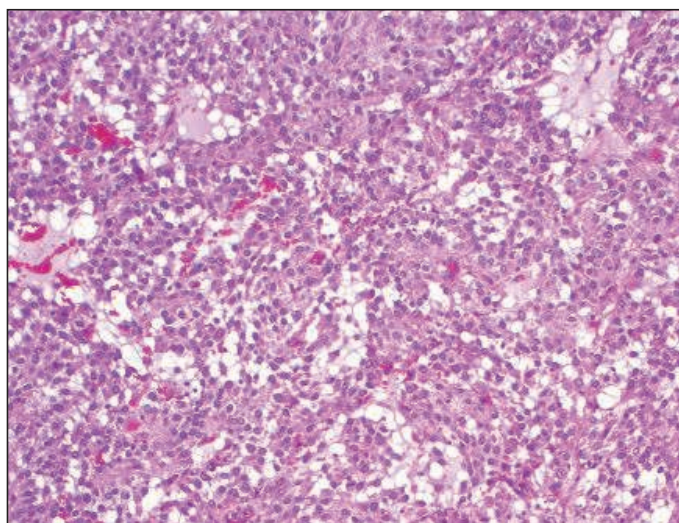
**Cell types in GIST:** The pathologist will describe the GIST cells' shape as spindle, epithelioid, or mixed. Overall, about 70% of GISTs are composed of spindle cells (long and skinny in shape, sometimes called fusiform), while 20% are composed of epithelioid cells (round or polygonal), and 10% contain a mixture of both types. Cell shape distribution varies among GISTs from different digestive tract organs. Almost all intestinal GISTs are of the spindle cell type, but about 40% of gastric GISTs (arising from the stomach) show epithelioid cells or mixed cell type. Epithelioid GISTs are more likely to be PDGFRA-mutant or to be wild-type than spindle cell GISTs. Spindle and epithelioid GIST cell types are shown in Figure 4.

**Cell characteristics:** The pathologist may note various other features that are not typical of normal cells. In general, in sarcoma grading, the more similar the tumor cells appear to normal cells, the more favorable the outcome may be. However, in GIST this relationship does not clearly hold true.

- **Nuclear atypia:** abnormal appearance of the nucleus of a cell.
- **Pleomorphism:** extreme variation in cell shape and size (including nuclei).



***Spindle cell GIST.***



***Epithelioid cell GIST.***

***Figure 4. GIST samples stained with H&E, viewed at 100X magnification.***

**Tissue structure characteristics:** Your report may mention patterns in the structure of the tissue (whorls, fascicles, palisades, sheets, nests, etc.), but this is of little significance in terms of prognosis.

**Serosal penetration:** If the tumor is quite small and is still contained within the wall of the GI tract, it is called “intramural.” Usually a larger tumor will grow outward through the wall of the digestive organ where it originated, penetrating the serosal membrane covering the muscular wall. Penetration of the serosa may be associated with an increased risk of metastasis within the abdominal cavity, but this is not one of the critical features for prognosis.

**Tumor vascularity (blood supply):** The pathologist may note how richly the tumor was served by blood vessels. Tumors cannot grow very large without developing new vessels to bring them blood.

## **Mitotic Count or Mitotic Rate**

Figure 5 illustrates the steps in the cell division cycle. Mitosis is the final step, when the cell actually separates into two. Mitosis means cell division, the process by which cells proliferate or reproduce. Tumors grow because the tumor cells divide too frequently. The more often each cell divides, the faster the tumor grows. The mitotic count is one of the most important parts of your pathology report because this proliferation indicator helps predict the probability that surgery was curative versus the probability that GIST might recur.

The cell cycle consists of two growth phases, G1 and G2, that separate the synthetic (DNA replication) and mitotic (cell division) phases. After mitosis, cells can enter the G0 resting phase for a variable amount of time. Under stimulation from a constitutively active KIT or PDGFRA receptor, the time that GIST cells spend in G0 is greatly reduced.

The mitotic count is one of the most important parts of your pathology report because it indicates how fast your GIST was growing. Higher mitotic rates strongly suggest an increased chance that the tumor will recur in the future, as



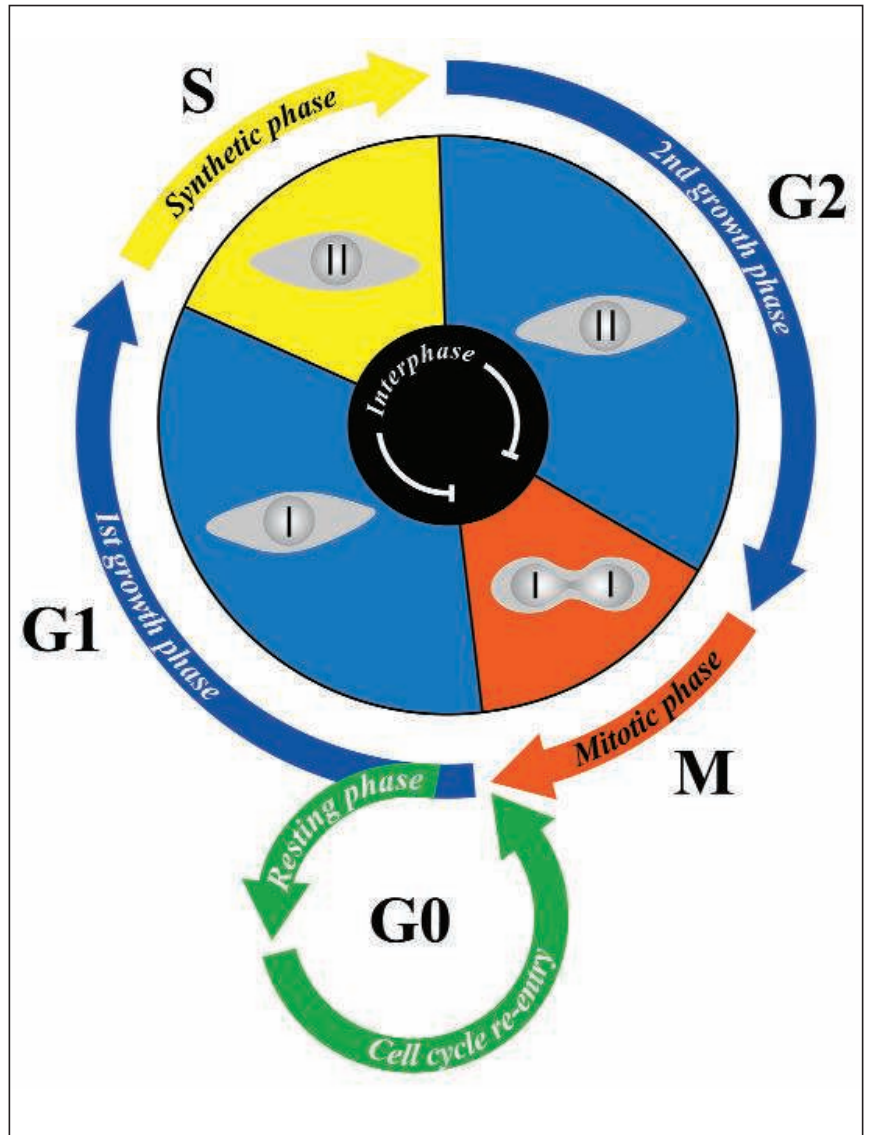
detailed in the section on prognosis.

The pathologist can see how many cells are in the division process when examining slides of tumor cells under the microscope. To determine mitotic rate, the pathologist literally counts the number of cells that can be seen undergoing mitosis (called mitotic figures) in a specified section of the tumor. In Figure 6 you can see the mitotic figures that the pathologist counts.

Different parts of the tumor may be growing more actively than others, so the pathologist should carefully evaluate different sections and perform the count on

the section with the highest mitotic rate that is found. Once that most actively growing section has been identified, the pathologist will examine 50 consecutive high-power fields (50 HPF) under the microscope to count mitoses.

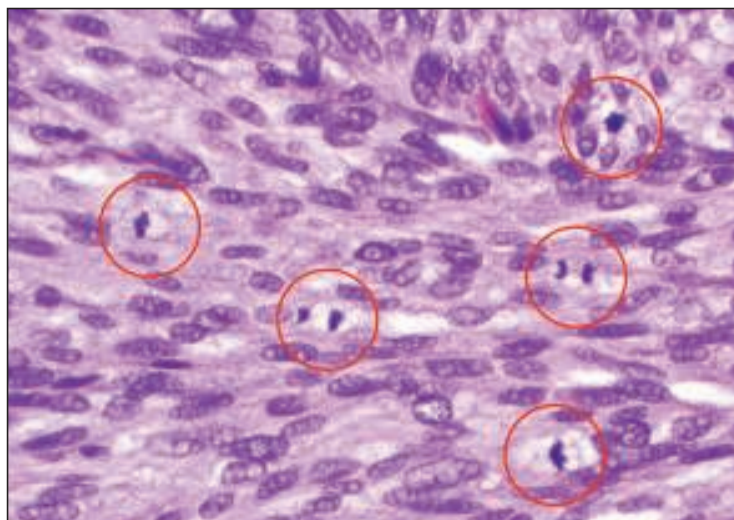
One high-power field is a standard measure of area, and 50 traditional HPF equals 5 square millimeters (5 mm<sup>2</sup>). If the pathologist uses a microscope with fields twice as big (called wide-field optics) then only 25 fields are needed to contain the same area of 5 square millimeters (5 mm<sup>2</sup>). The count will be reported as a ratio such as 3 / 50 HPF (3 mitoses per 50 HPF) or 15 / 50 HPF



**Figure 5: The Cell Cycle.**

(15 mitoses per 50 HPF). Values less than 5 / 50 HPF are desirable, and values over 20 / 50 HPF are exceptionally high.

Some pathologists also use an alternative indicator of tumor cell division called Ki-67 or MIB-1. This is an immunohistochemical stain that identifies cells in any non-resting stage of the cell cycle (anything but G0). The result is given as the percent of cells that have entered the cell cycle. This method and mitotic counts are similar in assessing cell proliferation, but the two do not easily translate one to the other, and extensive studies to validate the prognostic value of specific levels of nuclear MIB-1 reactivity have not been performed in GIST.

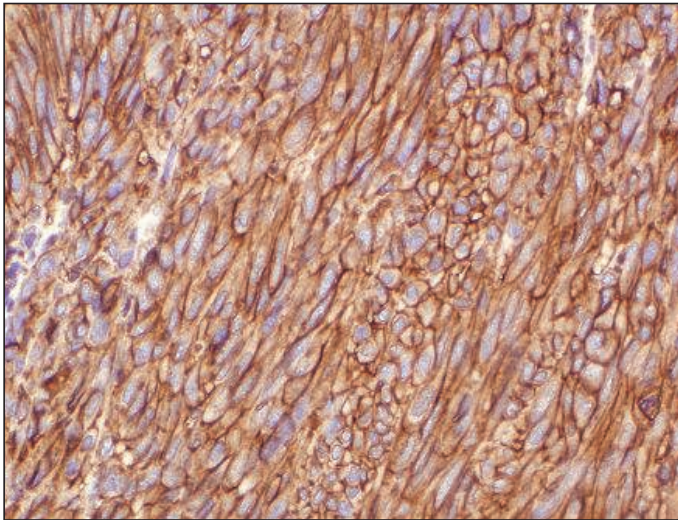


**Figure 6. GIST cells at 400X magnification with mitotic figures circled, illustrating what the pathologist looks for to count the mitotic rate.**

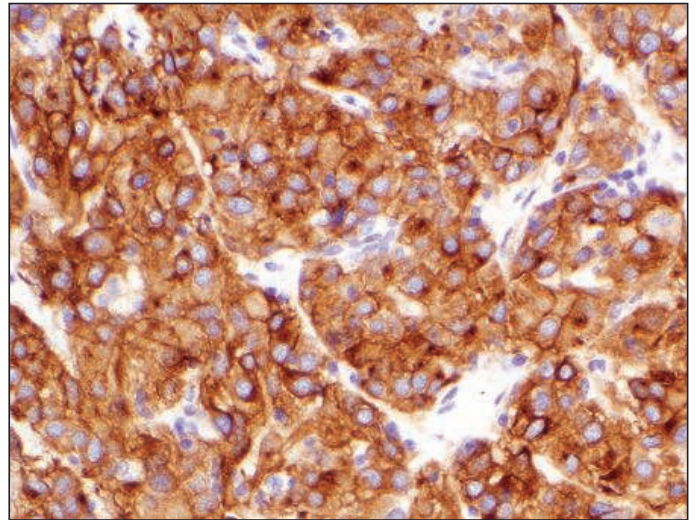
## Immunohistochemical Tests

Immunohistochemical tests use antibodies to detect whether selected proteins are present in cells. All cells have many parts composed of proteins, but cells of different types (such as muscle cells versus nerve cells versus bone cells) use different specific proteins for their particular cell functions. Antibodies can be prepared that will bind to the protein of interest in a sample of tumor cells. In this context, the protein being tested for is called an antigen. Binding of the antibody to the antigen forms a new target that can be stained to show its presence in the cells. Multiple steps are usually involved in performing immunohistochemical tests, but at the end the pathologist knows whether the tumor cells stain for the proteins that were tested for. Positive results for KIT immunohistochemistry are illustrated in Figure 7 by the brown staining.

Although staining for KIT protein (CD117) is usually diagnostic for GIST, the



***KIT-positive spindle cell GIST.***



***KIT-positive epithelioid cell GIST.***

***Figure 7. GIST samples viewed at 200X magnification with brown staining indicating positive results for KIT immunohistochemistry.***

pathologist often performs other tests as well to rule out competing diagnoses. The histologic appearance of the tumor, along with its location, suggests a few alternative tumor types to the pathologist, who selects a panel of tests to identify the correct diagnosis. A typical test panel might include the following immunohistochemical tests. They have no prognostic significance for GIST but are done to aid in differential diagnosis.

- **CD34** is positive in about 80% of gastric GISTs but only in about 50% of intestinal GISTs.
- **SMA** or smooth muscle actin is positive in about 30% of GISTs.
- **S-100** is positive in about 5% of GISTs.
- **Desmin** is positive in about 2% of GISTs, most commonly in GISTs that are negative for KIT.
- **Pan-cytokeratin** is positive in <1% of GISTs.

The main competing diagnoses for abdominal tumors are listed in Table 1, along with the immunohistochemical tests that indicate each one.

**Table 1. Abdominal tumor diagnoses competing with GIST and indicative immunohistochemical tests.**

<b>Cell shape</b>	<b>Tumor Type</b>	<b>Examples</b>	<b>Characteristic Immunohistochemistry</b>
Spindle	Smooth muscle tumors	Leiomyoma Leiomyosarcoma	smooth muscle actin + desmin +
	Neural tumors	Schwannoma Malignant peripheral nerve sheath tumor	S-100 protein +
	Fibrous tumors	Inflammatory fibroid polyp Solitary fibrous tumor	CD34 +
		Desmoid fibromatosis	smooth muscle actin + beta-catenin (nuclear) +
	Carcinoma	Spindle cell carcinoma	pan-cytokeratin +
Epithelioid	Melanoma	Melanoma	melan-A + HMB45 + S-100 protein +
	Perivascular tumor	PEComa (perivascular epithelioid cell tumor)	smooth muscle actin + HMB45 +
	Carcinoma	Clear cell carcinoma	pan-cytokeratin +

**Tests for KIT-negative GISTs.** About 5% of GISTs do not test positive for KIT (CD117). This group includes some (but not all) GISTs with mutations in the gene for PDGFRA, as well as some GISTs with mutations in the KIT gene, and some GISTs with neither mutation (wild-type). The immunohistochemical tests that can sometimes help to identify KIT-negative tumors as GIST include the following:

- **DOG1** – a marker that may be positive in KIT-negative GISTs (about 40%)
- **PDGFRA** – the growth factor receptor positive in GISTs with mutations in the gene for PDGFRA, but the available immunohistochemical tests are not widely used due to reliability issues.

## Diagnosis

Once the pathologist has described all the tests required for the individual case, the pathologist will state the diagnosis of GIST and often give a brief rationale for this conclusion. Some pathology departments use the term "gastrointestinal stromal sarcoma" (as opposed to gastrointestinal stromal tumor) for tumors that have greater malignant potential.

# GIST Prognosis: Risk Of Recurrence or Aggressive Behavior

**S**everal different schemes have been used to estimate the risk of recurrence, also called malignant potential, for gastrointestinal stromal tumor (GIST). Your pathology report may use one or more of the following categorizations. Both the NIH and the NCCN schemes apply to primary tumors that have not yet metastasized, but the AJCC scheme applies to both primary and metastatic GIST. Note that because these classifications were developed using data for GIST in adults, they may not be appropriate for use with the very rare pediatric GIST.

## NIH Consensus Risk Scheme for GIST

Developed at a consensus conference of experts and published in 2002, this scheme divides GISTs into risk groups based solely on tumor size and mitotic count. Four risk groups were defined as shown in Table 2. This risk table was based on expert experience and opinion, as there were only limited data available.

**Table 2. Risk of Aggressive Behavior in GISTs**

Reproduced from Fletcher et al, 2002, *Human Pathology* 33(5):459-465. Used with permission of Elsevier.

Risk Group	Size (largest dimension)	Mitotic Count
very low risk	< 2 cm	< 5 / 50 HPF
low risk	2-5 cm	< 5 / 50 HPF
intermediate risk	< 5 cm	6-10 / 50 HPF
	5-10 cm	< 5 / 50 HPF
high risk	> 5 cm	> 5 / 50 HPF
	> 10 cm	any mitotic rate

## NCCN Risk Classification for GIST

An improved risk scheme for GIST, developed by pathologists Miettinen and Lasota based on actual data, has been adopted by the National Comprehensive Cancer Network Task Force on GIST. This approach, shown as Table 3, evaluates risk based partly on tumor site of origin. Gastric GISTs are less likely to recur than tumors of similar size and mitotic rate from other GI tract sites.

**Table 3. Risk classification for primary GIST by mitotic index, size, and tumor site.**  
 Adapted from Miettinen and Lasota, 2006, *Seminars in Diagnostic Pathology* 23(2):70-83. Used with permission of Elsevier.

Tumor Parameters		Risk of Progressive Disease <sup>a</sup>			
Mitotic Index	Size	Stomach	Duodenum	Jejunum or Ileum	Rectum
≤ 5 per 50 HPF	≤ 2 cm	none	none	none	none
	> 2 ≤ 5 cm	very low (1.9%) low	low (8.3%)	low (4.3%)	low (8.5%)
	> 5 ≤ 10 cm	low (3.6%)	insufficient data	moderate (24%)	insufficient data
	> 10 cm	moderate (12%)	high (34%)	high (52%)	high (57%)
> 5 per 50 HPF	≤ 2 cm	none <sup>b</sup>	insufficient data	high <sup>b</sup>	high (54%)
	> 2 ≤ 5 cm	moderate (16%)	high (50%)	high (73%)	high (52%)
	> 5 ≤ 10 cm	high (55%)	insufficient data	high (85%)	insufficient data
	> 10 cm	high (86%)	high (86%)	high (90%)	high (71%)

<sup>a</sup> defined as metastasis or tumor-related death

<sup>b</sup> denotes small number of cases

Data based on longterm followup of 1055 gastric, 629 small intestinal, 144 duodenal, and 111 rectal GISTs.

## American Joint Committee on Cancer (AJCC) Staging for GIST

The AJCC is a joint effort by several professional organizations to define classifications for various cancer types for standardized description and treatment decisionmaking. The AJCC defines cancer staging as follows: "Staging describes the extent or severity of an individual's cancer based on the extent of the original (primary) tumor and the extent of spread in the body."

*The AJCC Cancer Staging Manual, 7th edition* introduced staging criteria for GIST to be used starting in January 2010. There had never been AJCC staging for GIST in the past, but pathology reports on new tumors and new biopsies from 2010 onward may use this scheme. If you have a diagnosis from earlier than 2010, you could see where your tumor would fall in this new scheme, but there is no real new information here – it employs the Miettinen and Lasota / NCCN criteria translated to the AJCC's classification known as "TNM" (tumor, lymph nodes, and metastasis).

- Tumor size yields a "T" category.
- Lymph node status yields an "N" category that is usually zero because lymph node spread is very rare in GIST (except in pediatric GIST).
- The "M" category indicates whether the GIST has metastasized yet.

See Table 4 for the AJCC categories of T, N, M, and mitotic rate for GIST.

Mitotic rate is combined with the TNM information to give a stage. The final scheme is shown in Table 5. Staging is different for gastric and omental versus other GISTs, indicating a greater risk of recurrence for non-gastric GISTs.

Stage 1 GISTs are low-risk tumors that are unlikely to recur after surgery, and Stage 4 GISTs represent metastatic disease that will likely benefit from treatment with molecularly targeted drugs such as imatinib or sunitinib. The intermediate stages 2 and 3 correspond to moderate and high risk of recurrence for GIST. Recommended treatment schemes for these tumor stages are evolving through active research, but treatment may also include targeted drugs. Genotyping of KIT and PDGFRA may be helpful in deciding the appropriate treatment approach and selecting a drug therapy.



**Table 4. Definitions of T, N, M, and Mitotic Rate for GISTs at all sites of origin.**  
 Used with the permission of the American Joint Committee on Cancer (AJCC), Chicago, Illinois.  
 The original source for this material is the *AJCC Cancer Staging Manual, Seventh Edition (2010)*  
 published by Springer Science and Business Media LLC, [www.springer.com](http://www.springer.com).

<b>Primary Tumor T</b>
TX: Primary tumor cannot be assessed
T0: no evidence for primary tumor
T1: tumor 2 cm or less
T2: tumor more than 2 cm but not more than 5 cm
T3: tumor more than 5 cm but not more than 10 cm
T4: tumor more than 10 cm in greatest dimension
<b>Regional Lymph Nodes (N)</b>
NX: regional lymph nodes cannot be assessed
N0: no regional lymph node metastasis
N1: regional lymph node metastasis
<b>Distant Metastasis (M)</b>
M0: no distant metastasis
M1: distant metastasis
<b>Mitotic Rate</b>
low mitotic rate: 5 or fewer mitoses per 50 HPF
high mitotic rate: over 5 mitoses per 50 HPF

**Table 5. Anatomic Stage / Prognostic Group for GIST by site of origin.**  
 Used with the permission of the American Joint Committee on Cancer (AJCC), Chicago, Illinois.  
 The original source for this material is the *AJCC Cancer Staging Manual, Seventh Edition (2010)*  
 published by Springer Science and Business Media LLC, [www.springer.com](http://www.springer.com).

Gastric GIST * Group	T	N	M	Mitotic Rate
Stage IA	T1 or T2	N0	M0	low
Stage IB	T3	N0	M0	low
Stage II	T1	N0	M0	high
	T2	N0	M0	high
	T4	N0	M0	low
Stage IIIA	T3	N0	M0	high
Stage IIIB	T4	N0	M0	high
Stage IV	any T	N1	M0	any rate
	any T	any N	M1	any rate
Small Intestinal GIST** Group	T	N	M	Mitotic Rate
Stage I	T1 or T2	N0	M0	Low
Stage II	T3	N0	M0	Low
Stage IIIA	T1	N0	M0	High
	T4	N0	M0	Low
Stage IIIB	T2	N0	M0	High
	T3	N0	M0	High
	T4	N0	M0	High
Stage IV	any T	N1	M0	any rate
	any T	any N	M1	any rate

\* Note: also to be used for omentum

\*\* Note: also to be used for esophagus, colorectal, mesentery, and peritoneum

# Pathology Reports for GIST

## Biopsy Samples and Reports

A biopsy contains only a small amount of tissue. Sometimes the sample is too small for the pathologist to describe tissue structure (how the cells are organized), but the individual cells can be described. Sometimes a needle biopsy will withdraw only a few useful tumor cells along with blood and necrotic fluid (dead cells and decomposing residue). The pathologist will not attempt to estimate prognosis on such a small sample, but the sample will be described and a diagnosis will be made, if possible. Unfortunately, sometimes the biopsy misses the tumor and only samples tissues next to the tumor. In this situation, the biopsy must be repeated.

The pathologist will select the most definitive tests to use on the limited biopsy sample in order to give a diagnosis, as there may not be enough tissue for every desired test. This list may include immunohistochemistry for KIT (CD117), CD34, smooth muscle actin, S-100 protein, desmin, and pan-cytokeratin.

Here is a sample report on a biopsy.

### **GASTRIC TUMOR, BIOPSY:**

GASTROINTESTINAL STROMAL TUMOR, spindle cell type.

Mitoses number 1 per 20 high power fields.

No necrosis identified.

Immunohistochemistry shows the following staining profile in tumor cells:

**Positive - KIT, CD34**

**Negative - desmin, S-100 protein**

*These findings support the above diagnosis.*

## Surgical Resection Samples and Reports on GIST

The surgical pathology report will contain much more information because the pathologist has adequate tumor tissue to work with. After describing the entire surgical specimen (everything that was removed), the pathologist samples areas of the tumor that appear to be growing most rapidly. In addition to your pathology report, you should read the surgeon's operation report for a description of your tumor's location and how it was removed (lifted away from adjacent organs, removed with adherent parts of adjacent organs "en bloc," etc.)

Here is a sample report on a resected tumor.

### **SMALL BOWEL RESECTION:**

GASTROINTESTINAL STROMAL SARCOMA, mixed epithelioid and spindle cell type (9 cm in greatest dimension),  
HIGH RISK (per 2010 NCCN guidelines).

Mitoses number 8 per 50 HPF.

No necrosis identified.

Tumor involves the full-thickness of the bowel wall and penetrates the serosa.

The proximal and distal small bowel resection margins are negative for tumor.

Immunohistochemistry performed on paraffin sections reveals the following staining profile in tumor cells:

Positive – KIT, DOG1

Negative – SMA, desmin, S-100 protein

## Reports on Treated GISTs

If your report describes a primary GIST or GIST metastasis removed after drug treatment, the report will differ in several ways from a pre-treatment report.

**Mitotic count** may be listed, but it is not comparable to the mitotic count of an untreated tumor since the drug usually reduces cell proliferation.

**Risk classification** is not possible (and is irrelevant for metastatic tumors since the tumor has already spread).

**Percent of viable cells** is one of the most informative facts about a treated tumor — the percent of living tumor cells remaining, in contrast to necrotic (dead) cells, and areas where tumor cells have been destroyed and only scarring (often described as “hyalinization”) remains. The smaller the percentage of viable tumor cells seen, the better the response to treatment has been although there may still be viable tumor cells in the tumor or elsewhere in the body. Sometimes a successfully treated tumor will become less cellular (“hypocellular”), meaning the tumor cell nuclei are farther apart with more intervening stroma and/or scar tissue, although the tumor cells are still viable. Even after removal of all visible metastatic disease, treatment is usually continued.

Some treated tumors that have grown resistant to targeted drug therapies like imatinib may show unusual changes that the pathologist can detect.

**Loss of KIT protein expression** means that tumor cells may no longer express KIT protein if the tumor has developed another pathway for survival and growth. For example, some treated GISTs have shown a “kinase switch” to AXL, an alternate growth factor. If the tumor stops testing positive for KIT protein, the pathologist may be uncertain whether this tumor is GIST or whether it is a new cancer.

**Change in morphology** means a change in cell appearance such as *differentiation* toward a different cell type (such as rhabdomyosarcomatous, which is skeletal muscle) or *dedifferentiation* toward more primitive cell forms. Such changes make it more difficult to be sure the tumor is GIST. Fortunately, these changes are very rare.

Here is a sample report on a tumor treated with drugs before resection.

**LIVER, PARTIAL HEPATECTOMY:**

METASTATIC GASTROINTESTINAL STROMAL SARCOMA, spindle cell type (4.5 cm in greatest dimension) with extensive (>95%) hyalinization, consistent with treatment effect.

Mitoses number less than 1 per 50 HPF.

The surgical resection margin is negative for tumor.

# Questions Patients Often Ask

- 1. Some of my pathology samples were shipped to another lab for analysis: does this mean my hospital pathologist is unfamiliar with GIST?**

Many labs routinely send away samples needing tests not regularly performed on-site. These might include immunohistochemistry and mutational testing.

- 2. My pathology report shows a mitotic count per 10 high-power fields (not 50 fields) or does not actually give any count but says “scant mitoses”: Is this reliable? Could it be re-counted if necessary?**

It is important to get an actual count of mitoses per 50 HPF because too small a sample may give unrepresentative results. Your surgeon or your oncologist can request the pathologist to provide a more complete analysis if the information would change the way your case will be managed. This is generally the case for a large sample (i.e., surgical resection specimen). In a small biopsy sample (core needle biopsy or endoscopic mucosal biopsy), there is usually not enough tissue for a mitotic count in 50 high power fields, but in certain cases the mitotic count in a smaller number of fields can help guide subsequent clinical management.

- 3. If my GIST pathology report seems to be missing some information compared to the descriptions in this discussion, should I ask for my sample to be sent to an expert sarcoma pathologist?**

You should feel comfortable asking your doctor about your pathology report. Your doctor may discuss the diagnosis with your pathologist,

who should be able to provide additional details if needed for risk assessment. In rare cases with unusual histologic patterns or unusual findings by immunohistochemistry (for example, KIT-negative GISTs), your pathologist may decide to send your slides to a pathologist with special expertise in GIST diagnosis to help confirm the diagnosis.

**4. My pathology report calls my tumor “benign” – what does this mean? Was it cancer? Do I need follow-up? Or does it mean the pathologist is not very familiar with GIST?**

If a GIST is said to be benign, that means that at the time of resection it had not metastasized, and the chance of future metastasis is deemed to be very, very small. Expert pathologists prefer not to use the word “benign” for GIST, as there is a chance of recurrence for all GISTs 2 centimeters in size or larger, and surgical removal is recommended for all such GISTs. Only GISTs smaller than 2 centimeters may be considered benign by some, since the risk of aggressive behavior approaches 0%. Some of these small tumors may be destined to acquire the characteristics that enable them to grow, but most “tumorlets” less than 2 cm do not grow larger and are commonly found in stomachs resected for other reasons and in autopsies.

**5. Why doesn't my pathology report give a “grade” or a “stage” for my GIST?**

The AJCC “TNM” staging was not available for GIST prior to 2010; therefore, older reports will not include a stage. Staging schemes for other sarcomas do not apply to GIST. Pre-2010 reports on primary tumors should compare to the risk-of-recurrence criteria available at the time of the report. The NIH consensus criteria became available in 2002, and the Miettinen and Lasota criteria were recommended by the NCCN in 2007. However, if older reports include the required information, it is possible to assign a stage using the 2010 AJCC staging

scheme later. Since the AJCC staging and the NCCN guidelines are essentially equivalent, either scheme is appropriate.

**6. Why doesn't my GIST pathology report include information about lymph nodes?**

GIST very seldom spreads to lymph nodes (unlike many cancers), with the exception of very rare GISTs in children. If the surgeon had noticed any lymph nodes that looked enlarged, they would have been removed. The pathologist will describe any nodes included in your surgical specimen.

**7. Do I need a second opinion about my GIST diagnosis or risk of recurrence since GIST is rare and many pathologists will seldom see GIST cases?**

Most pathologists are very aware of GIST and able to apply the criteria discussed above. Only in a small subset of unusual cases is additional expert opinion needed, and this is usually requested by the initial pathologist who first examined the case.

**8. Why doesn't my pathology report include mutation testing of the genes for KIT and PDGFRA?**

Some cancer centers do mutation testing automatically, but most do not. Rarely, mutational testing might be needed for diagnosis, if other test results are not definitive (such as KIT-negative GISTs and/or unusual immunohistochemical or morphologic features). Even if mutation testing is done, it may be reported separately from your surgical pathology report. Not all experts agree that mutation testing of every GIST is necessary prior to initial treatment.

**9. Do I need mutation testing on my GIST?**

Mutation testing should be considered in situations such as these:

- for intermediate-risk and high-risk non-gastric tumors, because



they could have the exon 9 KIT mutation, for which a higher drug dose would be appropriate if the tumor recurs

- for KIT-expression-negative tumors or others suspected of having PDGFRA mutations for which a drug other than imatinib might be appropriate if the tumor recurs
- for young patients whose tumors are more likely to be wild-type (lacking mutations in KIT or PDGFRA genes)

For further discussion of situations in which mutation testing can be helpful, see the webpage on this topic at [www.gistsupport.org](http://www.gistsupport.org)

**10. If I need mutation testing done now or later, how would I get that done?**

Your surgeon or oncologist can order this. Your pathologist might perform the analysis locally or else send samples away to a reference laboratory.

**11. Are there additional tests that may refine the risk of recurrence for GIST (either local recurrence or distant metastasis)?**

Pathologists and their colleagues have not reached consensus about additional testing that might help predict how likely it is that a surgically resected primary GIST might recur, but this is a focus of attention. Patients at high risk of recurrence might choose to take imatinib on a preventive basis (called adjuvant therapy); therefore, improved risk assessment is a clinically useful goal.

**12. How long will my tumor samples be kept in case I need more testing later?**

Formalin-fixed paraffin embedded (FFPE) blocks are retained for at least 10 years by most institutions; many retain this material indefinitely. All current tests for GIST can be performed using FFPE tissue; it is likely that any new testing will also be adapted to this

type of tissue preservation as it is the most common type of sample available.

Frozen samples may be stored and can be used for most tests, but they offer few advantages at this point since all testing has been optimized for FFPE use.

**13. If I later go to a different cancer center, will pathology testing be repeated?**

If you go to a specialized sarcoma clinic, your samples would usually be at least reviewed by an expert GIST pathologist. Some testing might be repeated if the slides are not provided by your home institution or if the expert pathologist is more comfortable with results from his or her own laboratory.

**14. Can I have extra tumor samples of my GIST stored for future use?**

This is a good idea because more is being learned about GIST every year. If new treatments are offered in the future, you may need a test on your tumor sample to know if the treatment applies to your type of GIST. You can arrange for extra samples to be saved by asking your surgeon in advance of your surgery. The surgeon will have to contact the pathology department to make arrangements. However, in most instances, the FFPE tumor sections taken for routine pathology will be enough for any additional testing.

**15. Can I contribute GIST samples to a tumor bank or to GIST researchers?**

Yes, and this is a great help to GIST research! You can give samples to the hospital where your surgery is done (if they are doing GIST research) as well as to other tumor banks or investigators. You must request this in advance to ensure that extra tissue is saved at the time of your surgery. See details on the website [www.gistsupport.org](http://www.gistsupport.org) at the page titled GIST Tissue Banks.

# Terminology in Pathology Reports

**Atypia:** abnormal shape and/or size of cells; may be focal (in particular spots) or diffuse (throughout the sample).

**Coagulative necrosis:** an area of tissue that has died due to lack of blood supply. Under the microscope the cells appear “ghostly” because they do not take up stain as living cells do, but their cell structure is preserved.

**Cystic degeneration:** cyst-like areas of degenerated or necrotic (dead) tissue within the tumor. While the degree of necrosis is important in other sarcomas for grading, this does not seem to be the case for GIST.

**Cytology:** examination of cells under the microscope; the study of cells. Usually this refers to an area of pathology that uses the features of individual cells (rather than the architectural properties of tissues) for diagnosis.

**Cytoplasm:** the parts of a cell between the cell membrane and the border of the cell nucleus (the nucleus is excluded).

**Dedifferentiation:** an abnormal process by which tumor cells lose their characteristic specialized form and become more primitive and less readily recognized as having a specific type of differentiation.

**Differentiation:** the normal process by which a less specialized cell becomes a more specialized cell type that is structurally and functionally different, recognizable as a more mature phenotype. The pathologist may form a working diagnosis of tumor type from the differentiation of the tumor cells and how closely they resemble normal cells of some tissue type.

**Dysplasia:** excess growth of abnormal-appearing cells, usually a precancerous condition in which cells show extra proliferation causing an accumulation of abnormal tissue that may be the start of a tumor.

**Eosinophilic cytoplasm:** cell cytoplasm that stains with the pink dye, eosin.

**Fascicles:** the appearance of bundles of cells within the structure of tumor tissue.

**Fusiform:** cells shaped like a spindle, wider in the middle and tapering toward the two ends.

**Golgi-pattern staining:** perinuclear dot-like staining on KIT immunohistochemistry; this feature has no known significance.

**Hemorrhage:** bleeding into an organ, body cavity or tumor.

**High cellularity, cell density:** tightly packed cells within the tumor, sometimes indicating faster cell proliferation.

**Hyalinization:** a form of fibrosis (scarring) characterized by abundant collagen and few cells.

**Hyperplasia:** excessive growth of normal-appearing cells in a tissue.

**Infiltration or invasion:** growth of tumor cells into the tissue of adjacent anatomical structures. Usually GISTs grow with non-invasive, pushing borders. Invasive or infiltrative borders may indicate a more aggressive tumor.

**Liquifactive necrosis:** an area of tissue that has died and the cell structure is no longer present because the dead cells have been digested, leaving a liquid-like appearance.

**Necrosis:** See coagulative necrosis and liquifactive necrosis.

**Nuclear atypia:** abnormal cell nuclei; can suggest malignancy in the correct context.

**Nuclear palisading:** alignment of cell nuclei so that there appear to be alternating blue and pink regions. There is no known significance of this pattern.

**Perinuclear vacuolization:** the presence of usually one or two large vacuoles (large intracytoplasmic vesicles) near the cell nucleus that can indent the nucleus. The significance of this is uncertain.

**Pleomorphic:** showing marked variation in cell size and shape.

**Serosal penetration:** GISTs normally grow outward from their origin in the wall of the GI tract, eventually piercing the outer covering (serosal membrane) and growing within the abdominal cavity (peritoneum).

**Skeinoid fibers:** thread-like structures often seen in the tissue of GISTs from the small intestine. Their significance is uncertain.

**Ulceration:** describes damage to the inner lining of the GI tract (the mucosa) at the point where a GIST undermines and creates a defect in the inner lining of the bowel through which blood or necrotic material from the GIST may enter the GI tract.

# Additional Reading

## **Gastrointestinal stromal tumours: ESMO Clinical Practice Guidelines for diagnosis, treatment and follow-up.**

P. G. Casali & J.-Y. Blay, on behalf of the ESMO/CONTICANET/EUROBONET Consensus Panel of Experts. *Annals of Oncology* 21 (Supplement 5): v98–v102, 2010. Free access at this link:

[http://annonc.oxfordjournals.org/content/21/suppl\\_5/v98.full.pdf+html](http://annonc.oxfordjournals.org/content/21/suppl_5/v98.full.pdf+html)

## **NCCN Task Force Report: Update on the Management of Patients with Gastrointestinal Stromal Tumors.**

G.D. Demetri et al. *Journal of the National Comprehensive Cancer Network* Volume 8 Supplement 2 (April 2010). Free access at this link:

[http://www.jnccn.org/content/8/Suppl\\_2/S-1.full.pdf+html](http://www.jnccn.org/content/8/Suppl_2/S-1.full.pdf+html)

## **Soft Tissue Sarcoma (NCCN Clinical Practice Guidelines in Oncology series).**

G.D. Demetri et al for the NCCN Soft Tissue Sarcoma Panel.

This document, updated at least annually, includes flow charts for GIST diagnosis and treatment. To access this document complete a free registration at this link:

[http://www.nccn.org/professionals/physician\\_gls/f\\_guidelines.asp](http://www.nccn.org/professionals/physician_gls/f_guidelines.asp)

See more resources at [www.gistsupport.org](http://www.gistsupport.org)



**GIST Support International** is an *all-volunteer* nonprofit organization created by an internet-based community of patients and friends. Our mission is to provide education and support worldwide to people living with GIST through ...

**Our website** at [www.gistsupport.org](http://www.gistsupport.org)

- Featuring up-to-date medical information about GIST and its treatment
- Showing experts' answers to patients' questions
- Sharing stories and essays by people affected by GIST
- Guiding patients to the latest effective therapies and clinical trials
- Suggesting sources of financial assistance

**Our e-mail listserv** for patients, family, and anyone interested in GIST

- Offering a safe place where individuals can ask questions
- Sharing practical advice and emotional support
- Forming an online community of friends who face GIST together

**Our e-mail listserv for pediatric and wild-type GIST**

- Serving the special needs of rare young patients with GIST
- Offering a community for parents and young patients

**Our GIST support Wiki** at [http://gistsupport.medshelf.org/Main\\_Page](http://gistsupport.medshelf.org/Main_Page)

- Listing practical strategies for coping with GIST
- Summarizing ways to alleviate symptoms and treatment side effects
- Collecting tips about a variety of topics that concern GIST patients

**Our telephone help line** at (215) 340-9374

**Our Phone Pals:** phone friends for those who prefer talking to typing

**Please contact us if we can help you!** E-mail: [gsi@gistsupport.org](mailto:gsi@gistsupport.org)



Dr. Jason Hornick is Associate Professor of Pathology at Harvard Medical School and Associate Director of Surgical Pathology and Director of Immunohistochemistry at Brigham and Women's Hospital. He has published widely in soft tissue tumor pathology, gastrointestinal pathology, and diagnostic immunohistochemistry, including many studies and reviews on GIST and c-kit. His research focuses on defining diagnostic criteria for soft tissue tumors, identifying features associated with malignancy and aggressive behavior, and translating scientific discoveries to clinical

practice. His goal is to provide new tools for surgical pathology to improve tumor classification and identify potential therapeutic targets for new treatments. When not working, he enjoys spending time with his wife and 7-year-old twins, a boy and a girl.



Dr. Alexander Lazar is a sub-specialized pathologist concentrating solely on clinical diagnosis and molecular genotyping for sarcoma (and also genotyping for melanoma). He is an Associate Professor in the multidisciplinary Sarcoma Research Center at M. D. Anderson Cancer Center where he works closely together with Drs. Dina Lev and Raphael Pollock and focuses on early genetic changes in sarcomagenesis. He has authored or co-authored many publications on various aspects of sarcoma pathology and translational research (and a bit of related skin pathology). Alex is a member of the American

Joint Cancer Committee (AJCC) Soft Tissue Sarcoma (Staging) Task Force and Committee on Cancer subcommittees for Soft Tissue Sarcoma and GIST pathology reporting for the College of American Pathologists (CAP). When not working, he enjoys spending time with his wife and children (aged 3 and 6 and very active), playing basketball and soccer/futsal, and foreign travel. He is an assistant coach of his son's soccer team and a big fan of international soccer.



[www.gistsupport.org](http://www.gistsupport.org)  
[gsi@gistsupport.org](mailto:gsi@gistsupport.org)  
(215) 340-9374

*This booklet explains the diagnosis of GIST and tells patients and families what they need to know to discuss treatment plans with their doctors.*



*"I found this booklet highly informative yet easy to read, full of useful and accurate information. I recommend this resource to all GIST patients and their families and health-care providers."*

**Jonathan Trent, MD PhD**, Associate Professor of Sarcoma Medical Oncology  
at the University of Texas MD Anderson Cancer Center

*"This booklet is an excellent and comprehensive resource for patients and families interested in understanding the pathology of GIST, written by two highly regarded GIST pathology experts."*

**Suzanne George, MD**, Clinical Director of the Center for Sarcoma and Bone Oncology  
at Dana-Farber Cancer Institute

Developed through an educational grant from Novartis Oncology.

Copyright © 2010 by GIST Support International

